

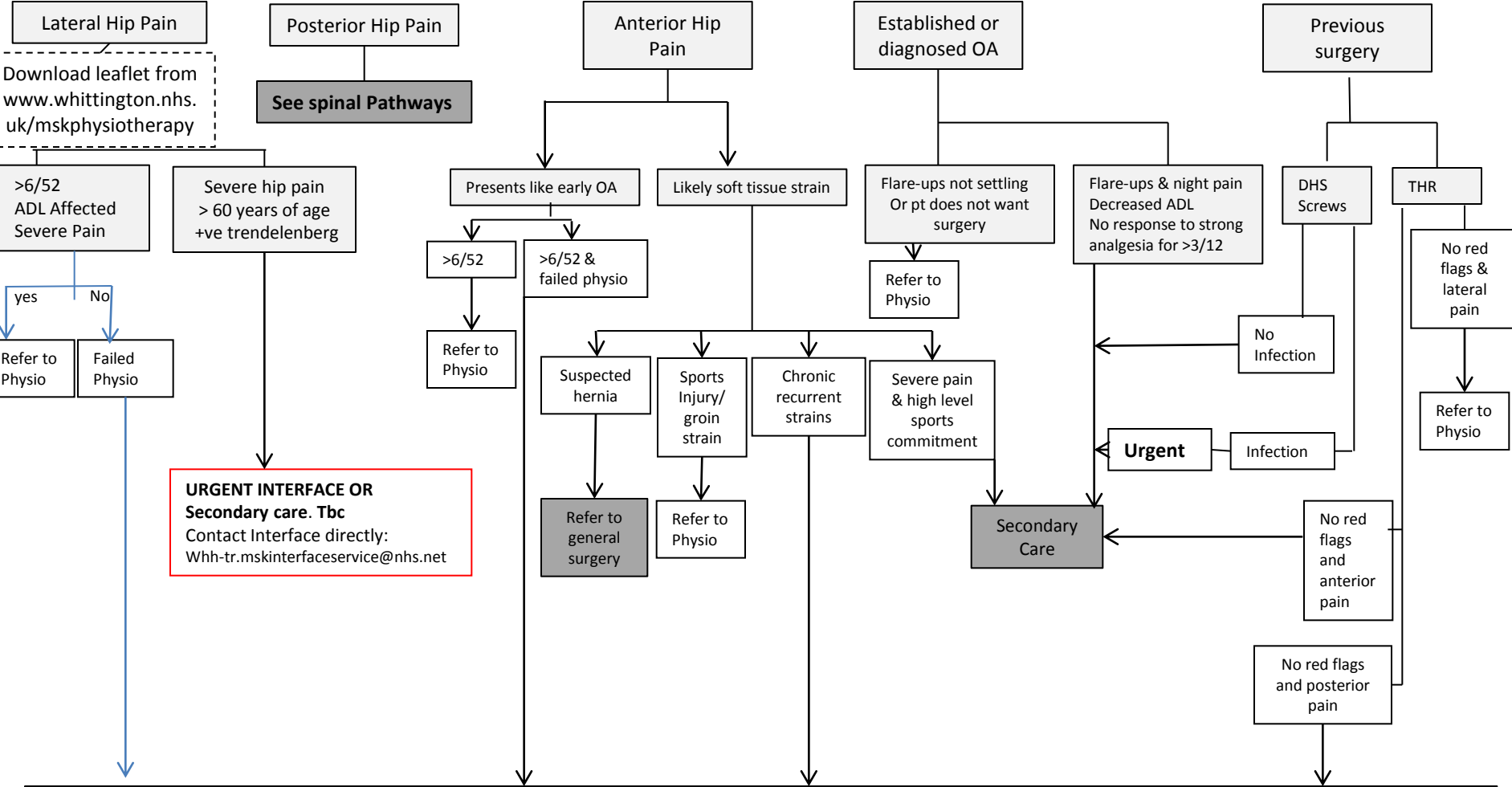
# Hip

If loosening or lucency seen on x-ray after arthroplasty refer to secondary care.  
Resurfacing of hip <1 year with increased pain (not x-rayed – should be ?)

**Red Flags**  
Acute THR dislocations  
THR Metal on metal suspected #  
Infection  
Avascular necrosis diagnosed (AVN).

Refer to secondary Care

**AVN**  
Excruciating night pain  
Unable to weight bare +/- hip #  
+/- HIV/steroid or alcohol usage  
+/- sickle cell anaemia



**MSK INTERFACE FOR : Further investigation/Injection therapy/Onward referral as appropriate.**